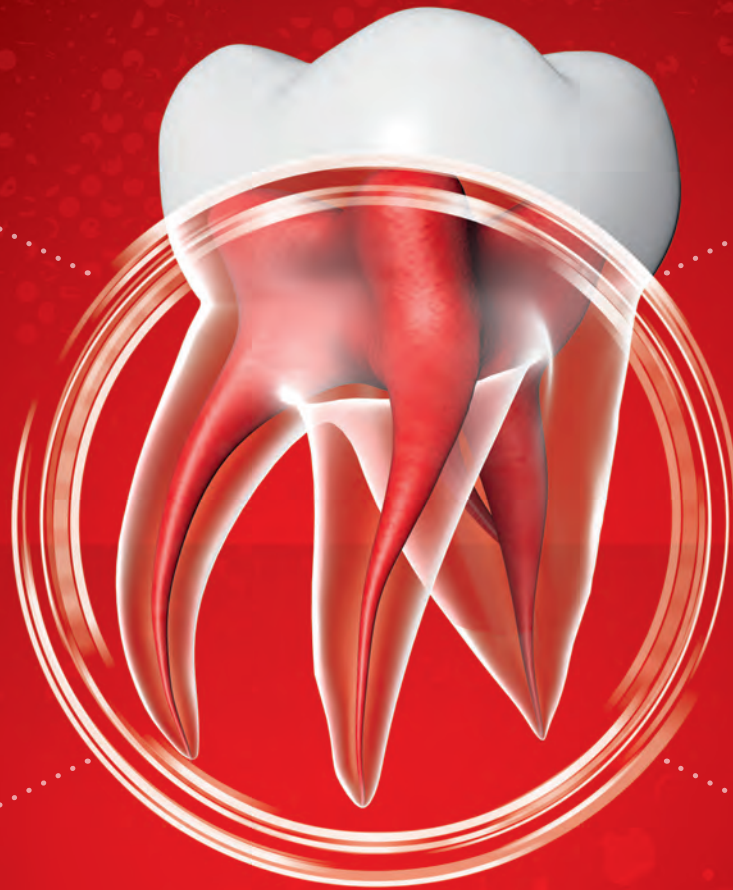

Endodontics

/// ACTIVE
BIOSILICATE
TECHNOLOGY

Biodentine[®]

Dentin Substitute



Biodentine[®]: Save the root, Save the tooth

1

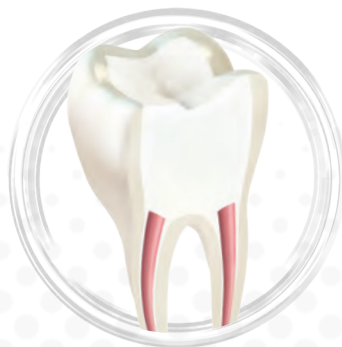Bioactivity triggers **regeneration**

- High biocompatibility with all dental tissues
- Biodentine[®] increases the mineral density of dentin through calcium ion release
- Biodentine promotes cell proliferation and supports periradicular healing

2

Outstanding seal with secure placement

- Crystallization inside the dentin tubules allows a tight interface with dentin and ensures strong resistance to leakage
- Biodentine sets in moisture in only a few minutes allowing fast repair procedures
- Biodentine shows high wash-out resistance and high push-out bond strength avoiding material dislodgement during the restorative procedure ^(1,2)



When it comes to special endodontic treatments, predictability can sometimes be difficult. Biodentine[®] enhances your success rates due to innovative and bio-oriented properties.

Technical Insights

Proven biocompatibility and bioactivity for endodontic repairs

- High biocompatibility assessed and evidenced through many scientific publications
- High release of calcium ions to increase the mineral density of root canal dentin⁽⁵⁾
- Shows both osteogenic and angiogenic properties to promote soft and hard tissue healing⁽⁶⁾
- High purity tricalcium silicate with no aluminum inclusions or trace metals^(7,8,9)

Tight seal supporting root longevity after root repair

- Mineral tag formation in the dentin tubules ensures strong micromechanical retention and a tight consistent seal
- High resistance to leakage supporting clinical success for endodontic repair procedures^(10,11)
- High pH (=12) inducing antimicrobial properties reducing the risk of reinfection⁽¹¹⁾

Product properties adapted for a moist environment

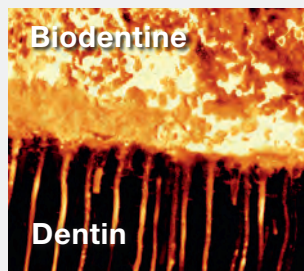
- Physical properties are not affected by contact with tissue fluids and blood due to Biodentine's hydraulic nature⁽¹²⁾
- Biodentine doesn't wash out and stays in place
- High push-out bond strength, unaffected by the use of endodontic irrigation solutions^(1,2)

Biodentine shows high incorporation of Ca and Si (µm) in dentin


Phosphate-buffered saline immersion	Ca		Si	
	Biodentine™	MTA	Biodentine	MTA
24h	66.8 (5.1) a	14.4 (3.8) b	17.6 (2.5) a	13.8 (2.2) a
7 days	116.8 (10.1) a	77.8 (13.5) b	71.2 (10.0) a	61.0 (8.9) a
30 days	212.2 (26.4) a	166.8 (10.1) b	160.2 (16.1) a	115.4 (24.0) b
90 days	296.0 (26.0) a	206.6 (15.1) b	275.8 (28.9) a	171.2 (33.4) b

Mean (SD), n=5
Mean values followed by different letters in the same line of the same element are significantly different (P<0.05)
MTA, mineral trioxide aggregate

Source : Han, Okiji, IEJ, 2011

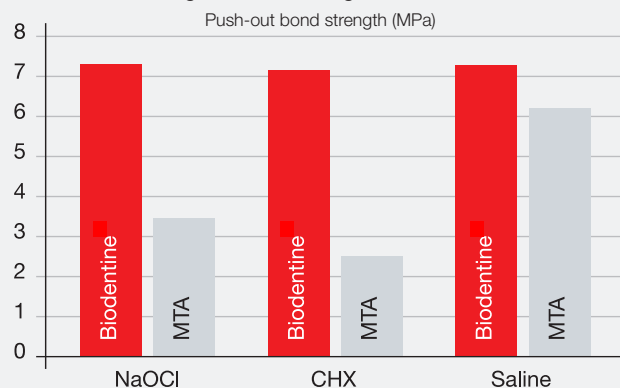


Biodentine cement labelled with fluorescein dye which has moved from the cement into the dentin tubules. Notice the plugs of material in the tubule openings.
Courtesy Dr Amre Atmeh, King's College London



Mineral tags inside dentin tubules.
Courtesy Prof. Franquin, Koubi, Dejou, University of Marseille

Biodentine shows higher resistance to dislodgement, regardless of the irrigation solution

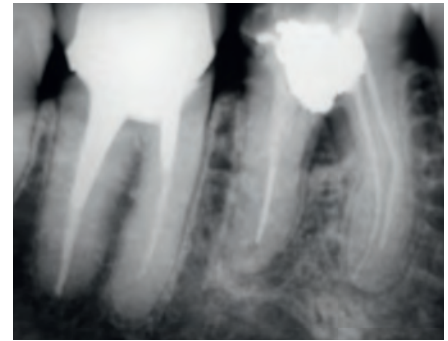


Source : Guneser et al., JOE, 2013

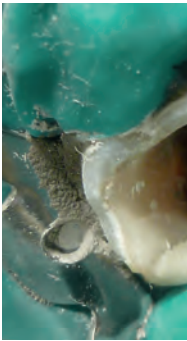Clinical cases

Perforation

Perforations of the root canal and of the pulp chamber floor usually are the most difficult accidents to solve and with uncertain prognosis. Biodentine has high sealing properties and is easy to place particularly in areas difficult to access. The setting time is a major advantage as work can be continued in the same operating session.



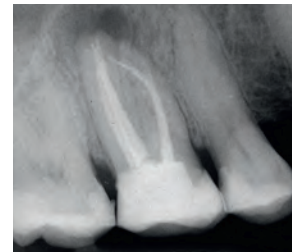
Initial X-Ray showing radiopaque substance in the pulp chamber and a peri-radicular lesion.



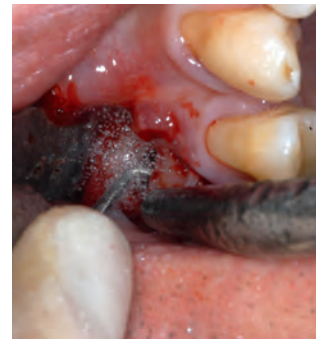After removal of the restorative material, a perforation is noticed on the pulp chamber floor.

Apical surgery

For successful apicoectomy, retrograde sealing of resected root canals is essential because gutta-percha alone is known not to be capable of inducing osseous regeneration at the root tip. Biodentine shows a positive effect on osseous cells and allowed, in this case, complete osseous regeneration 6 months after treatment. ⁽³⁾



61-year-old patient presented with pain and swelling in the region of #16. The radiograph obtained showed apical brightening and a fractured root canal instrument at tooth #16 protruding over the apex of the mesiobuccal root canal.



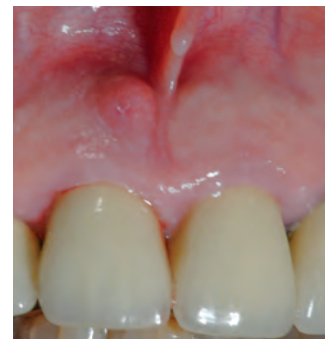Both mesiobuccal root canals were retrogradely prepared and cleaned with an angled, diamond-coated ultrasound probe.

Resorption

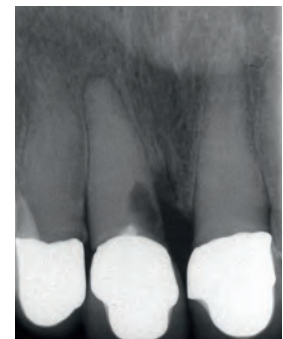Cervical root resorption mostly occurs directly beneath the epithelial attachment and is caused ultimately by an injury to the periodontium.

Biodentine is easy to place, sets fast, shows a tight seal and causes no tooth discoloration. ⁽⁴⁾

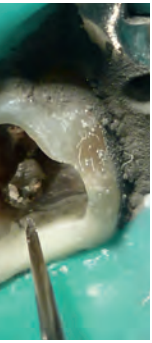Biodentine can effectively treat root resorptions.



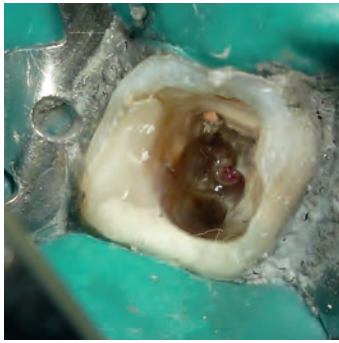
Inflammation Tooth #8.



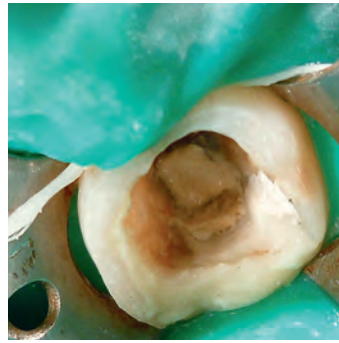
Initial X-ray findings with cervical root defect.



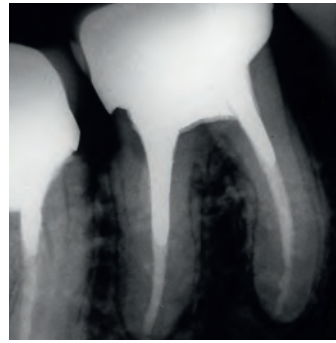
Coronal amalgam is removed. Chamber floor is exposed.



Amalgam is removed. Granulation tissue is exposed with bleeding and pain on pressure.

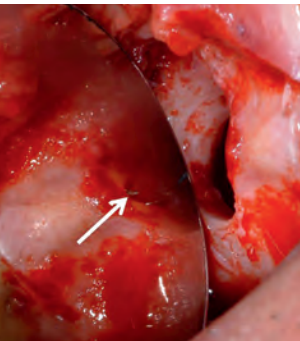


Biodentine is prepared and the cavity is filled layer by layer without pressure.

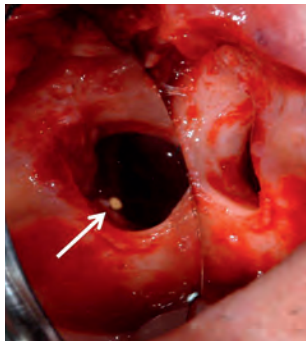


1-year follow-up.

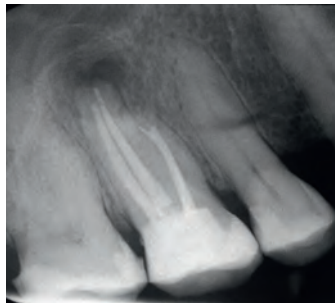
Case courtesy of Dr. Irene Lorenzo, Montevideo, Uruguay



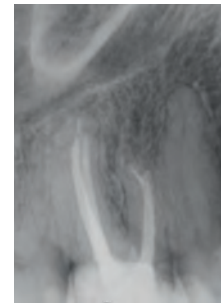
The arrow indicates the exposed fractured root canal instrument at the mesiobuccal root.



Apicoectomy was performed in order to remove granulation tissue and the fractured instrument.

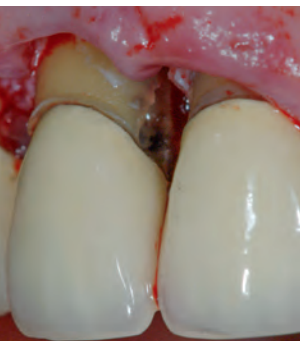


The radiograph obtained immediately postoperatively shows an osseous defect about the mesiobuccal root tip. The fractured root canal instrument was completely removed.

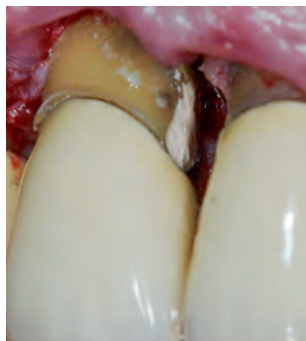

Even 3 1/4 years after the procedure, apical stability was found.

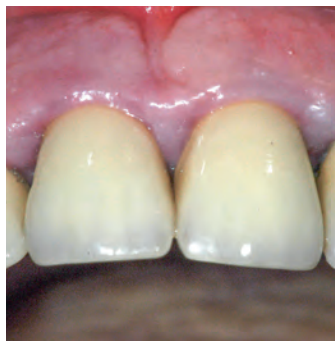Case courtesy of Prof. Tili Dammaschke, Münster, Germany



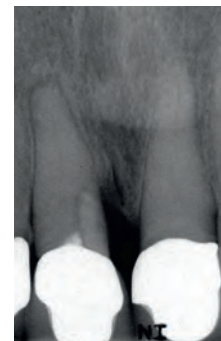
Condition after excochleation of the granulation tissue.



Closure of the cavity with Biodentine.



Clinical picture after 12 months.



X-ray findings 1 year post-op.

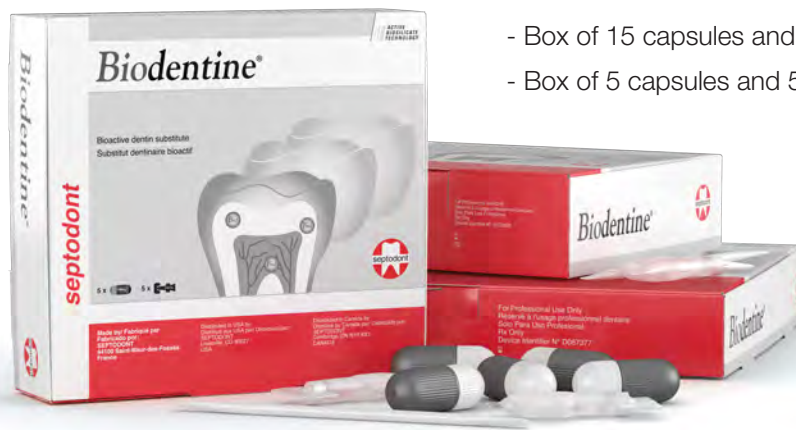Case courtesy of Dr. Peter Robotta, Münster, Germany

Authors	Title	Journal	Year	Ref.
Firla, Markus T., DR.	Direct pulp capping with a bioactive dentin substitute	Septodont Case Studies Collection, No. 2	2012	1
Guneser MB, Akbulut MB, Eldeniz AU.	Effect of various endodontic irrigants on the push-out bond strength of Biodentine and conventional root perforation repair materials	Journal of Endodontics	2013	2
Laurent P, Camps J	About I, Biodentine induces TGF- B2 release from human pulp cells and early dental pulp mineralization	International Endodontic Journal	2012	3
Camilleri, J. , MPhil	Staining Potential of NEOMTAPlus, MTAPlus, and Biodentine Used for Pulpotomy Procedures	Journal of Endodontics	2015	4
Han L, Okiji T.	Uptake of Calcium and Silicon released from calcium silicate based endodontic materials into root canal dentin	International Endodontic Journal	2011	5
Costa F, Sousa Gomes P, Fernandes MH.	Osteogenic and Angiogenic Response to Calcium Silicate-based Endodontic Sealers	Journal of Endodontics	2016	6
Camilleri J.	Characterization and hydration kinetics of tricalcium silicate cement for use as a dental biomaterial	Dental Materials	2011	7
Camilleri J, Sorrentino F, Damidot D.	Investigation of the hydration and bioactivity of radiopacified tricalcium silicate cement, Biodentine and MTA Angelus	Dental Materials	2013	8
Camilleri J, Kralj P, Veber M, Sinagra E.	Characterization and analyses of acid- extractable and leached trace elements in dental cements	International Endodontic Journal	2012	9
Katge FA, Shivasharan PR, Patil D.	Sealing ability of Mineral Trioxide Aggregate Plus™ and Biodentine for repair of furcal perforation in primary molars: An in vitro study	Contemporary Clinical Dentistry	2016	10
Sinkar RC, Patil SS, Jogad NP, Gade VJ.	Comparison of sealing ability of ProRoot MTA, RetroMTA, and Biodentine™ as furcation repair materials: An ultraviolet spectrophotometric analysis	Journal of Conservative Dentistry	2015	11
Subramanyam D, Vasantharajan M.	Effect of Oral Tissue Fluids on Compressive Strength of MTA and Biodentine: An In vitro study	Journal of Clinical Diagnosis and Research	2017	12



Available in:

- Box of 15 capsules and 15 single-dose pipettes
- Box of 5 capsules and 5 single-dose pipettes



Septodont 205 Granite Run Drive · Suite 150 · Lancaster, PA 17603 · USA

Please visit our website for more information: www.septodontusa.com Or call: 1-800-872-8305

